



IDIOPATHIC TOOTH RESORPTION IN DOGS

Jennifer Tjepkema, DVM



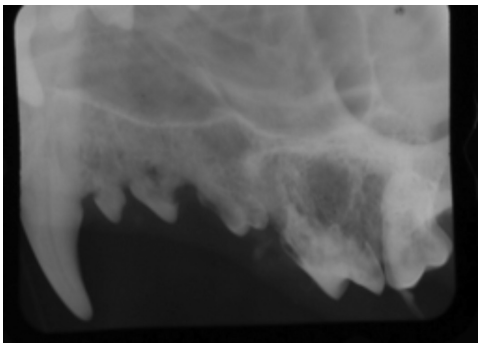
IDIOPATHIC TOOTH RESORPTION IN DOGS

Tooth resorption is a progressive, potentially painful and poorly understood disease that affects many species. The disease has been well recognized in people and cats but not in canines. This disease was once thought rare but now is more commonly diagnosed in dogs.

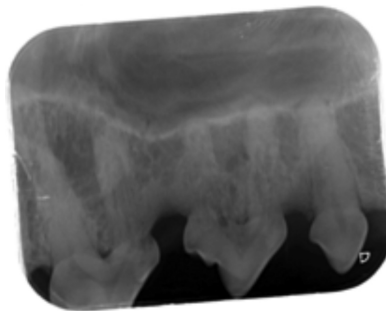
Juvenile teeth unlike adult teeth are resorbed and shed. It is not understood why in some dogs and cats, odontoclasts, the cells responsible for the resorptive process, are activated. Tooth resorption can occur in any breed and affect any dog at any age, but typically tooth resorption is observed in older dogs.

Tooth resorption below the attached gingiva is thought not to be painful (not reported painful by people) but lesions above the attached gingiva are known to be extremely painful. It can be very difficult to visualize a lesion above the attached gingiva. Typically the only signs are localized gingivitis or vague clinical signs of oral pain. Because the lesions often occur in older dogs, owners believe the clinical signs are related to aging. Dogs can become withdrawn, have a decreased appetite and may no longer play with their toys. Some dogs show more obvious clinical signs of pain such as severe drooling, reluctance to have their faces touched, painful when yawning or refusing to eat hard food or not wanting to eat at all. In extreme cases dogs can become aggressive due to significant pain when touched.

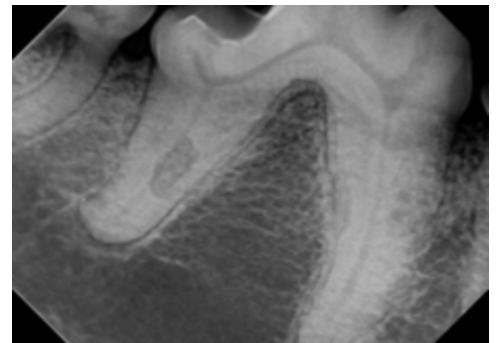With a history of possible oral pain, a conscious oral examination can yield clues to the presence of tooth resorption; such as brittle appearing teeth and/or localized gingivitis, asymmetrical accumulation of calculus/plaque, intrinsic staining of the crowns (usually a pinkish hue). Dental radiographs are essential to diagnosing and determining how and when to treat teeth affected by resorptive lesions. Tooth resorptive lesions are progressive and painful. They require treatment when above the attached gingiva. Dental radiographs help determine the extent and type of tooth resorptive lesions (type 1, 2 or 3), which dictates the treatment with either extraction or crown amputation.



RADIOGRAPH A



RADIOGRAPH B



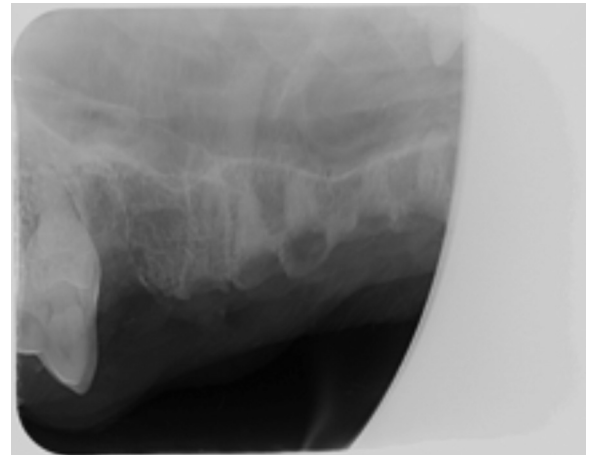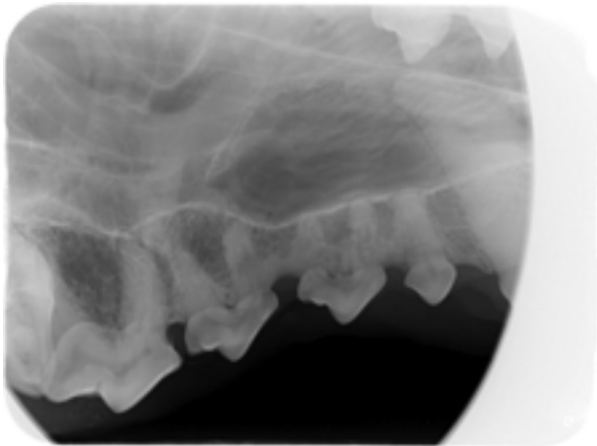
RADIOGRAPH C

Radiograph A: Example of Type 2 TR Lesions. Radiograph B: Example of Type 2 TR Lesion. Radiograph C: Distal root of the right mandibular first molar affected by Type 1 TR and the mesial root by Type 2 tooth resorption (TR).



IDIOPATHIC TOOTH RESORPTION IN DOGS

In summary, lesions that are below the attached gingiva are harder/trickier to decide when to treat. Tooth resorption is a progressive disease but the rate in which the disease progresses is not known and can be different in each tooth and pet. Some lesions can be present for years before progressing and sometimes they can progress rapidly (weeks). If the tooth resorption is not painful then it might be more beneficial for the patient to not treat the tooth but instead to monitor the tooth so the patient can retain the function of that tooth. Generally speaking, resorption that is radiographically more apical on the roots can be monitored whereas lesions closer to the alveolar bone would potentially benefit from more aggressive treatment. Ultimately, each tooth and each patient must be evaluated individually to determine prognosis, risk of anesthesia versus benefit of treatment and the client's long-term finances and goals for the treatment of their pet.



Radiograph on the left: Before Treatment and Radiograph on the right after treatment: Extraction of the mesial-buccal and distal-buccal roots of 108 with crown amputations of 107 and 106

